Human Anatomy Word Search

Puzzle 99

S X L R I L I A C T M E T E J A
B L U E H J F D L Z V R Z I U H
L P M L O R B I T A L N F G N B
H M B A C O N N E C T I V E I P
O H A T I E I T O Q X J J Y L E
J Z R I Z D P M B U Y Y K L A L
Q S F O J D Y H U R Y Q A H T V
Y A I N G U I N A L A I S M E I
V C O X M Q O D A L C N G K R C
W R P Z T N V T O I I I C K A G
F A T R G F I K F R A C Z H L R
L L E V Y P E R N V X N W G A J
K G C X I E E W H O I L V M D M
J H T C H P S D B U A Y L E B A
O V C C U B P P A Y L A V O Z H
V O W S I B G Y Q N P O A K X I

AXIAL
BRANCH
CEPHALIC
CHEEK
CONNECTIVE
ILIAC
INGUINAL
LUMBAR
OCCIPITAL
ORBITAL
PALMAR
PELVIC
RELATION
SACRAL
SUPERFICIAL
UNILATERAL

Human Anatomy Word Search

Puzzle-Solution 99

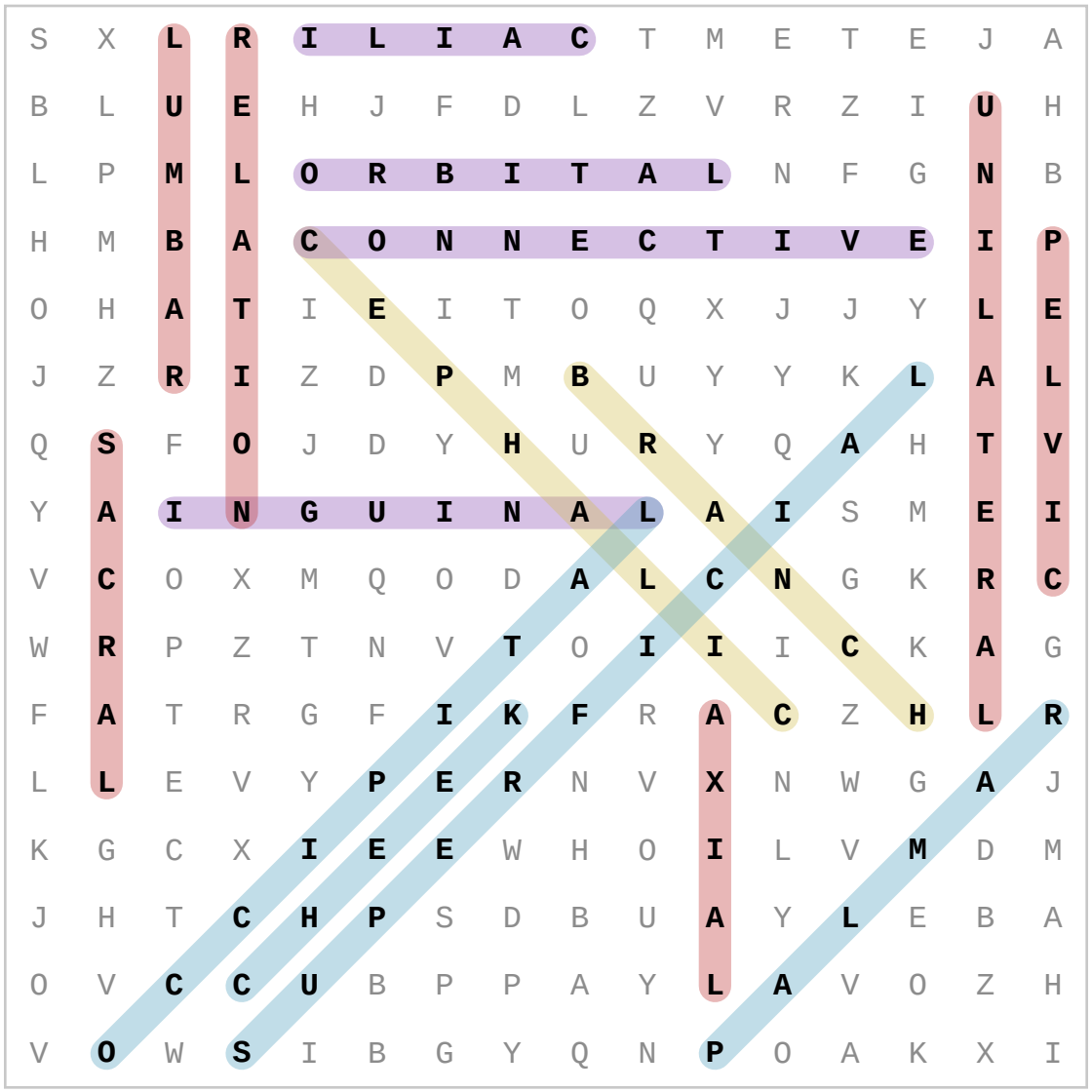

AXIAL
BRANCH
CEPHALIC
CHEEK
CONNECTIVE
ILIAC
INGUINAL
LUMBAR
OCCIPITAL
ORBITAL
PALMAR
PELVIC
RELATION
SACRAL
SUPERFICIAL
UNILATERAL